



Peeling: Ancient Treatment – New Possibilities

How to make patients happy

Dansk Dermatologisk Selskab

Billund Denmark, Fredag 20.01.2023

Oliver Ph. Kreyden President SGEDS Immediate Past President IPS *PraxisKlinik Kreyden* Switzerland www.kreyden.ch



Peeling: Ancient Treatment – New Possibilities

How to make patients happy

Dansk Dermatologisk Selskab

Billund Denmark, Fredag 20.01.2023

Oliver Ph. Kreyden President SGEDS Immediate Past President IPS *PraxisKlinik Kreyden* Switzerland www.kreyden.ch



Peeling: Ancient Treatment – New Possibilities

How to make patients happy

Dansk Dermatologisk Selskab

Billund Denmark, Fredag 20.01.2023

Oliver Ph. Kreyden President SGEDS Immediate Past President IPS *PraxisKlinik Kreyden* Switzerland www.kreyden.ch



Peeling: Ancient Treatment – New Possibilities

How to make patients happy

Dansk Dermatologisk Selskab

Billund Denmark, Fredag 20.01.2023

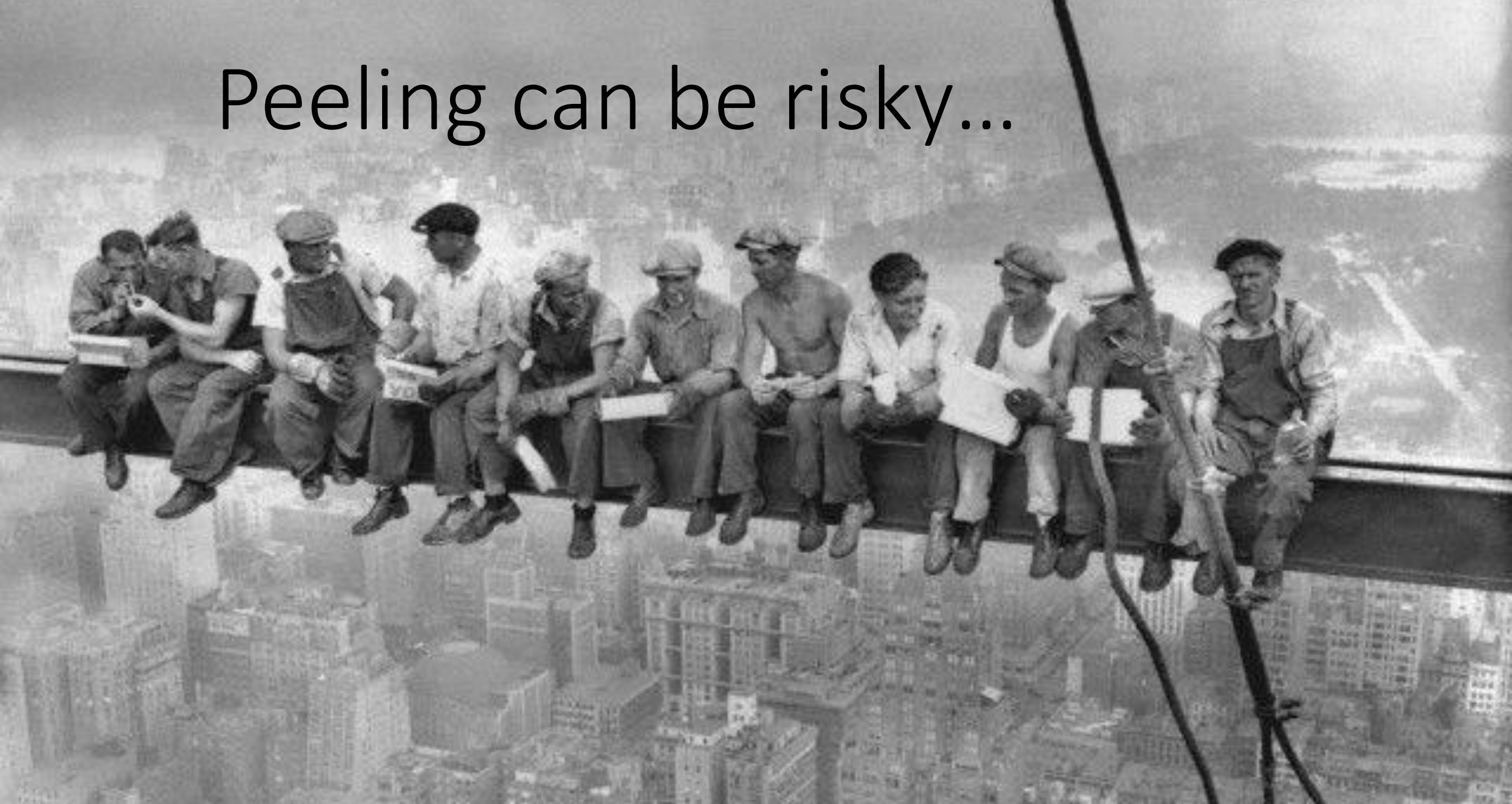Oliver Ph. Kreyden President SGEDS Immediate Past President IPS *PraxisKlinik Kreyden* Switzerland www.kreyden.ch

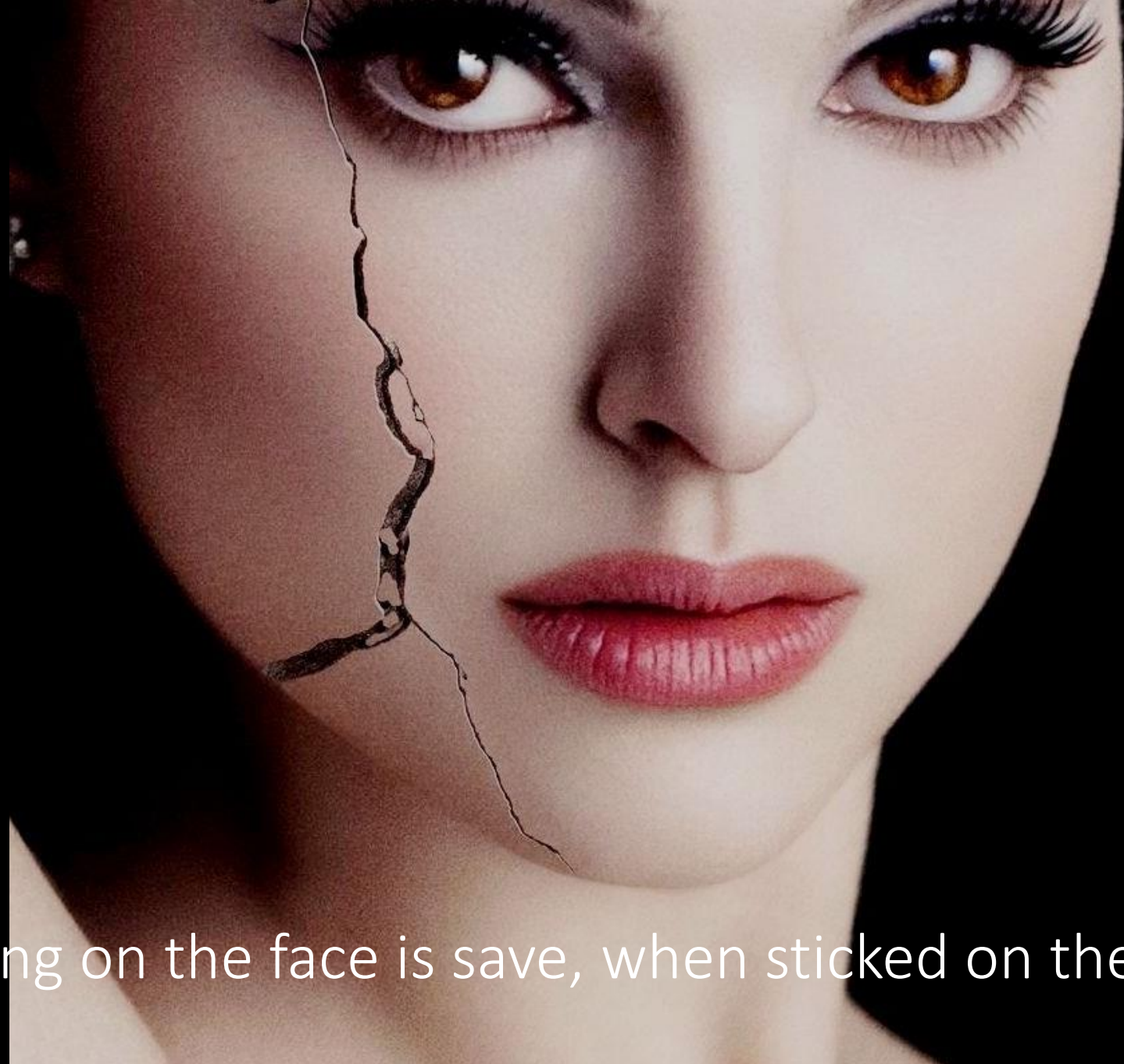
History of Peeling



- 16th bc keratolytic solution for rejuvenation
- 1882 *Paul G. Unna*
Salicylic acid, TCA, Resorcin and Phenol to treat scars
- 1942 *JJ.Ellers and S. Wolff*
Phenol and Resorcin in combination of cryo therapy for ablative rejuvenation
- 1961 *Thomas J. Baker and Howard L. Gordon, Miami*
present modified Phenol solution with Septisol and Croton oil

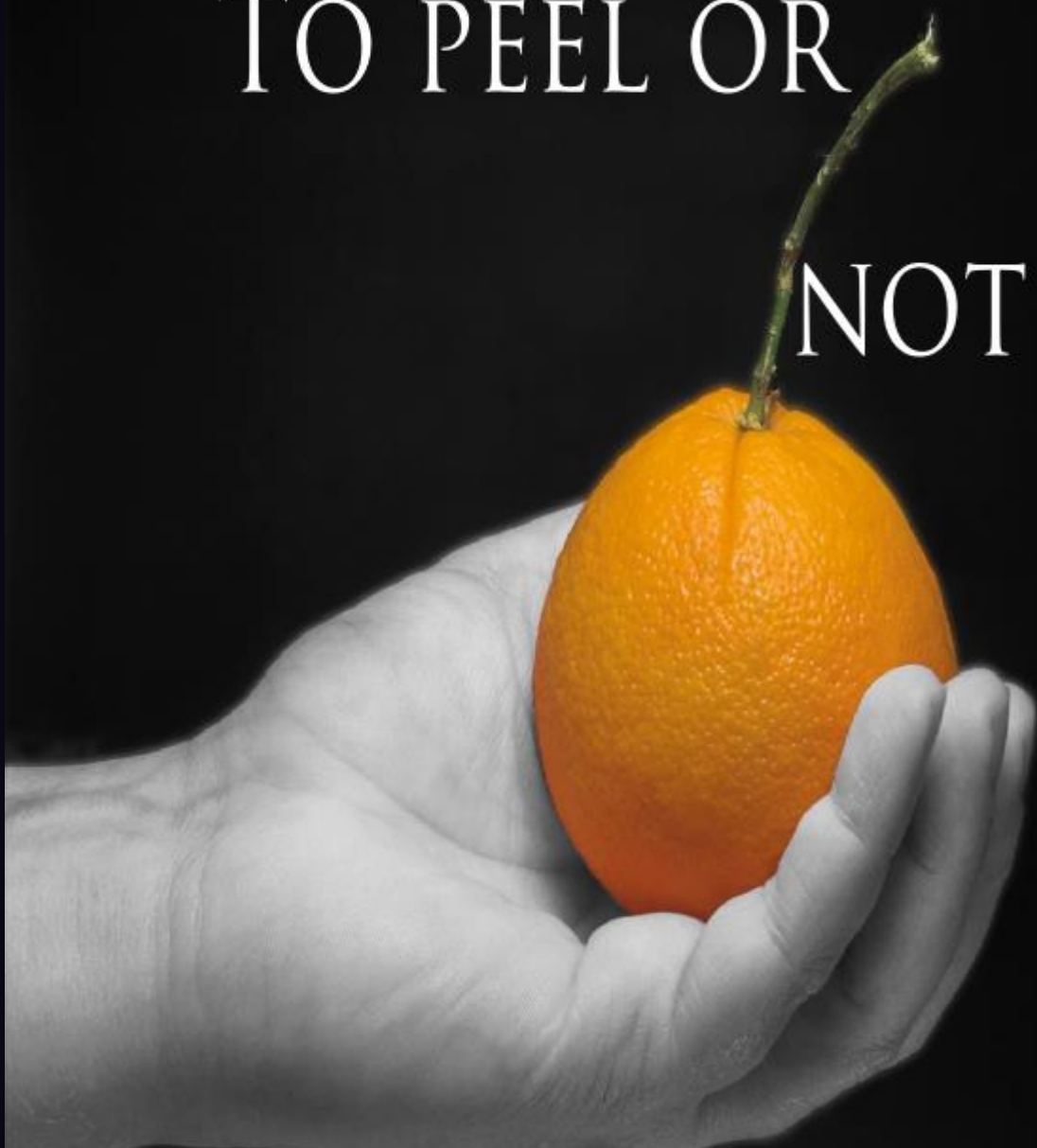
Peeling can be risky...





Peeling on the face is save, when sticked on the protocol

TO PEEL OR
NOT TO PEEL



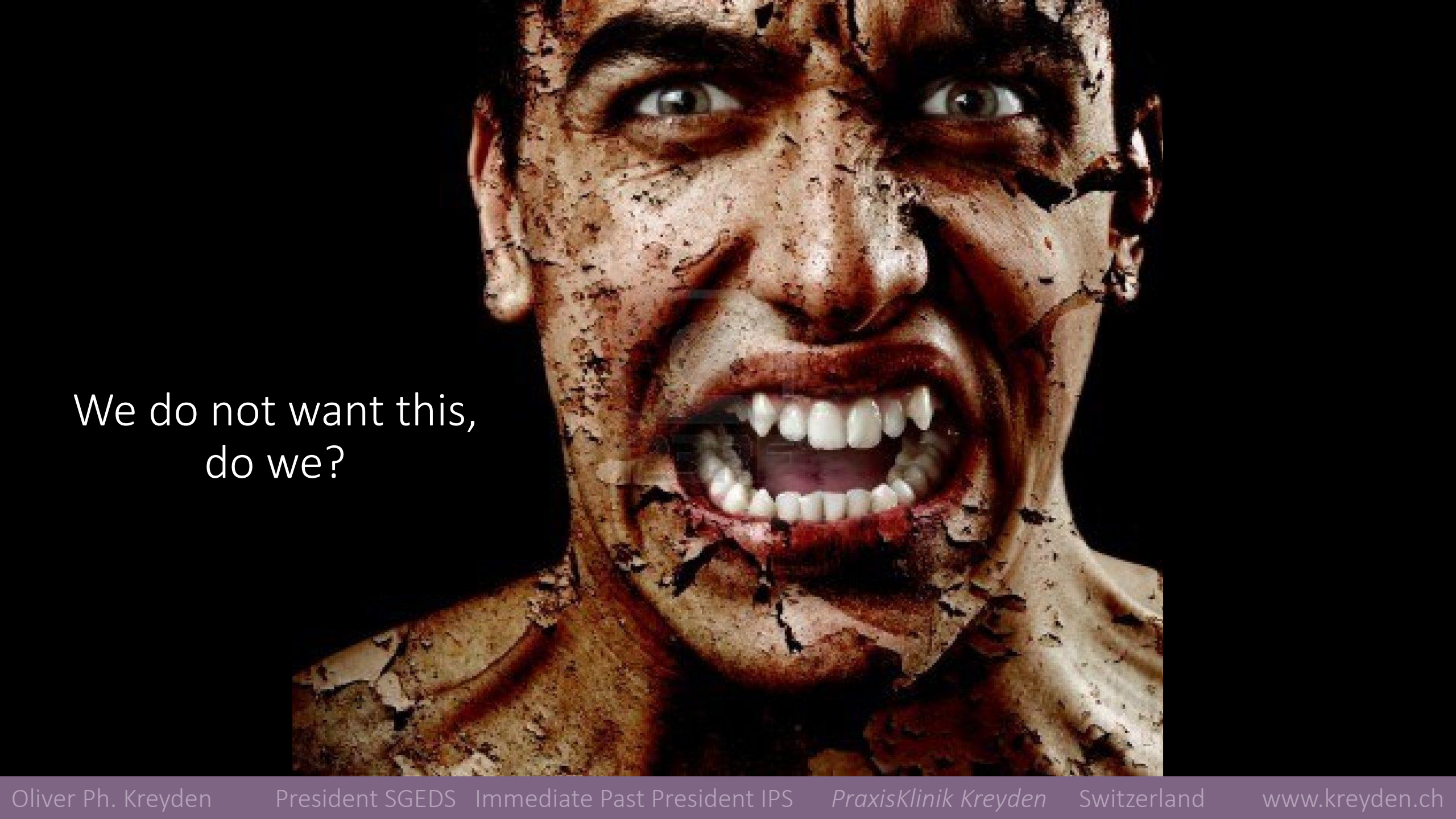
Dr. Neighbour



I do it since ages...



Steve Mc Curry



We do not want this,
do we?


An engraving depicting Hippocrates and his associates. Hippocrates is seated on the left, wearing a dark robe, with his right arm extended towards a group of men standing before him. The group includes several bearded men in classical attire, some holding a large, ornate cylindrical object. The background shows architectural details like columns and a statue.

primum nihil nocere

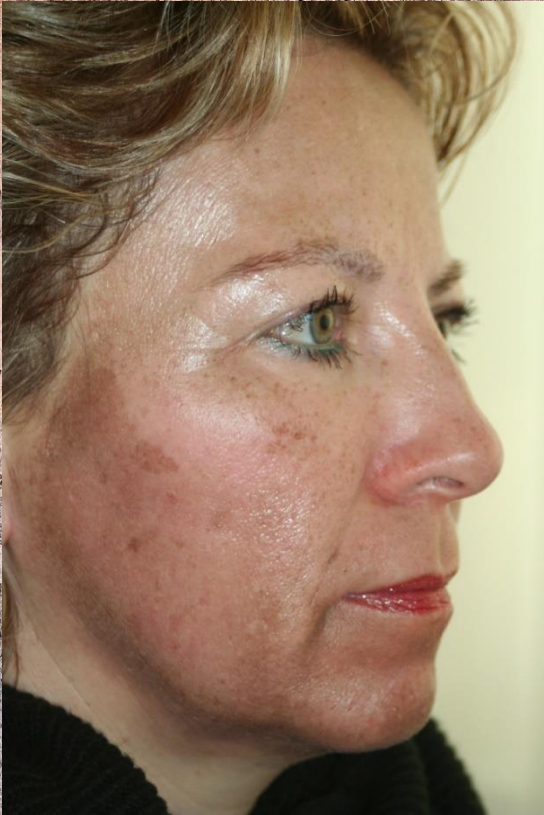Hippocrates 460 – 370 bc



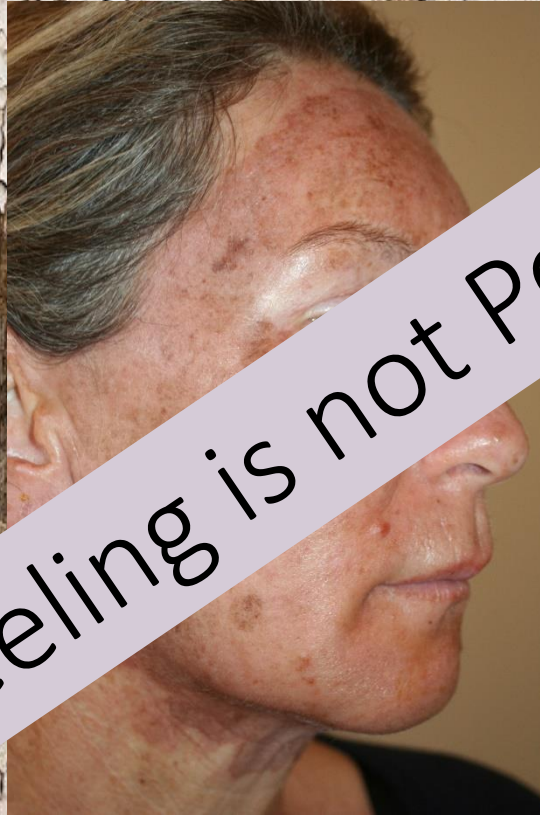PEELING IS NOT PEELING



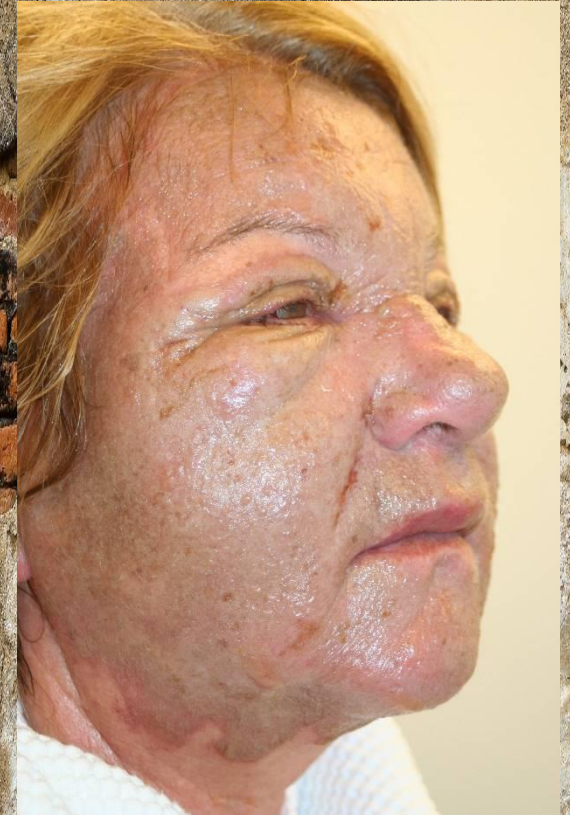However the Downtime as well!



Superficial Peeling



Middle deep Peeling



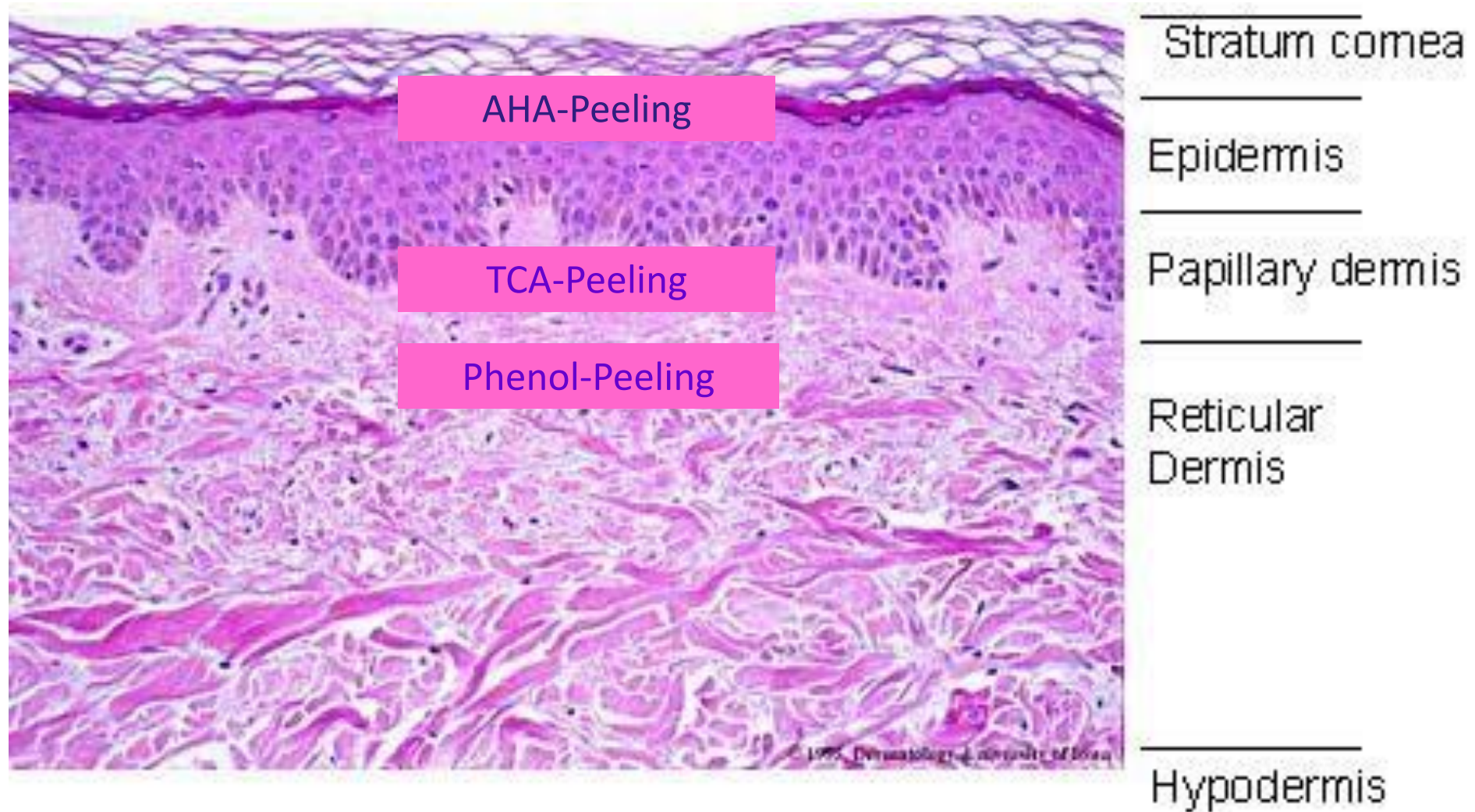
Deep Peeling

What is the Effect of Peelings?

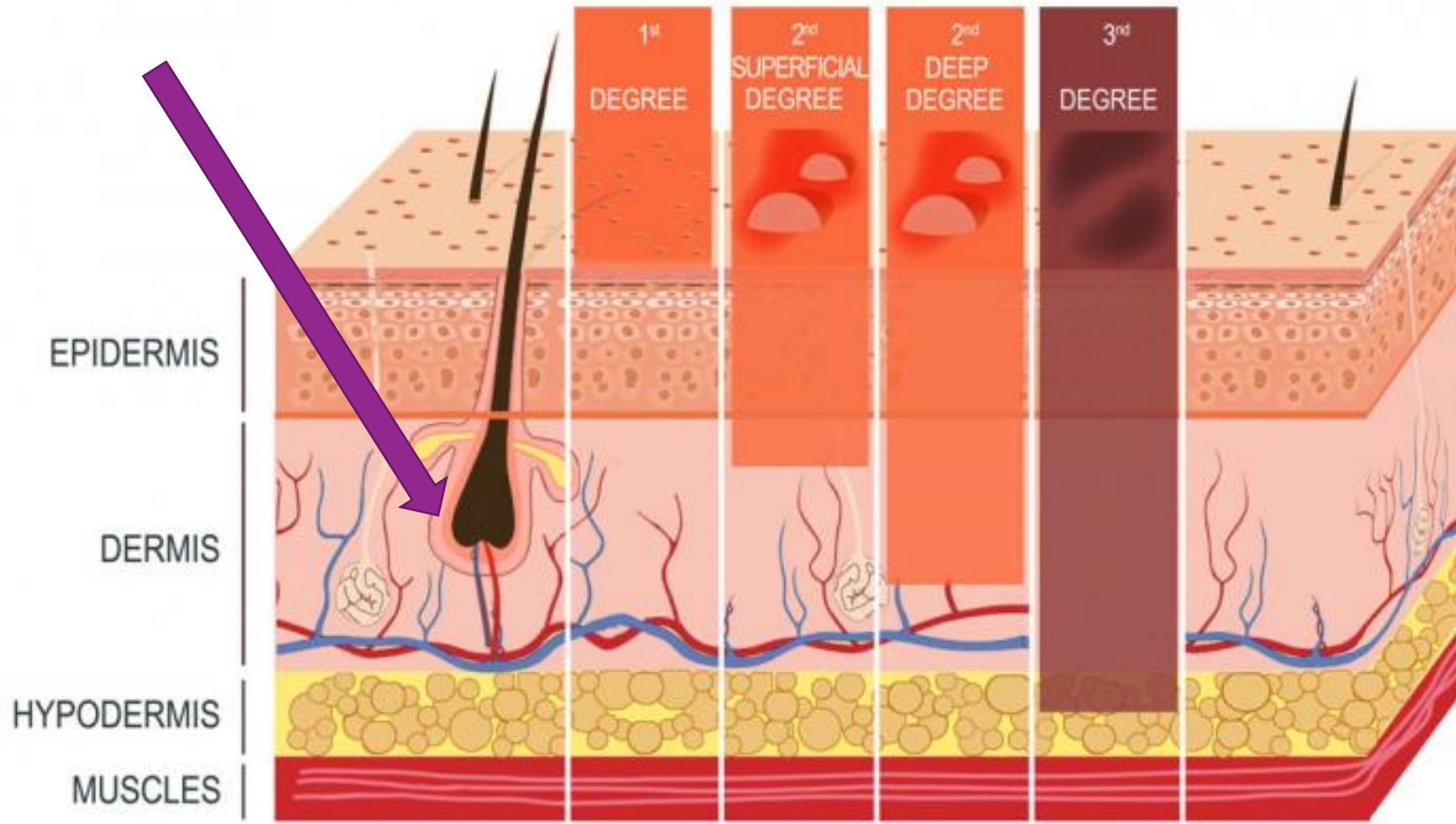
- Destruction
- Exfoliation
- Inflammation
- Collagen Synthesis

... in a controlled manner

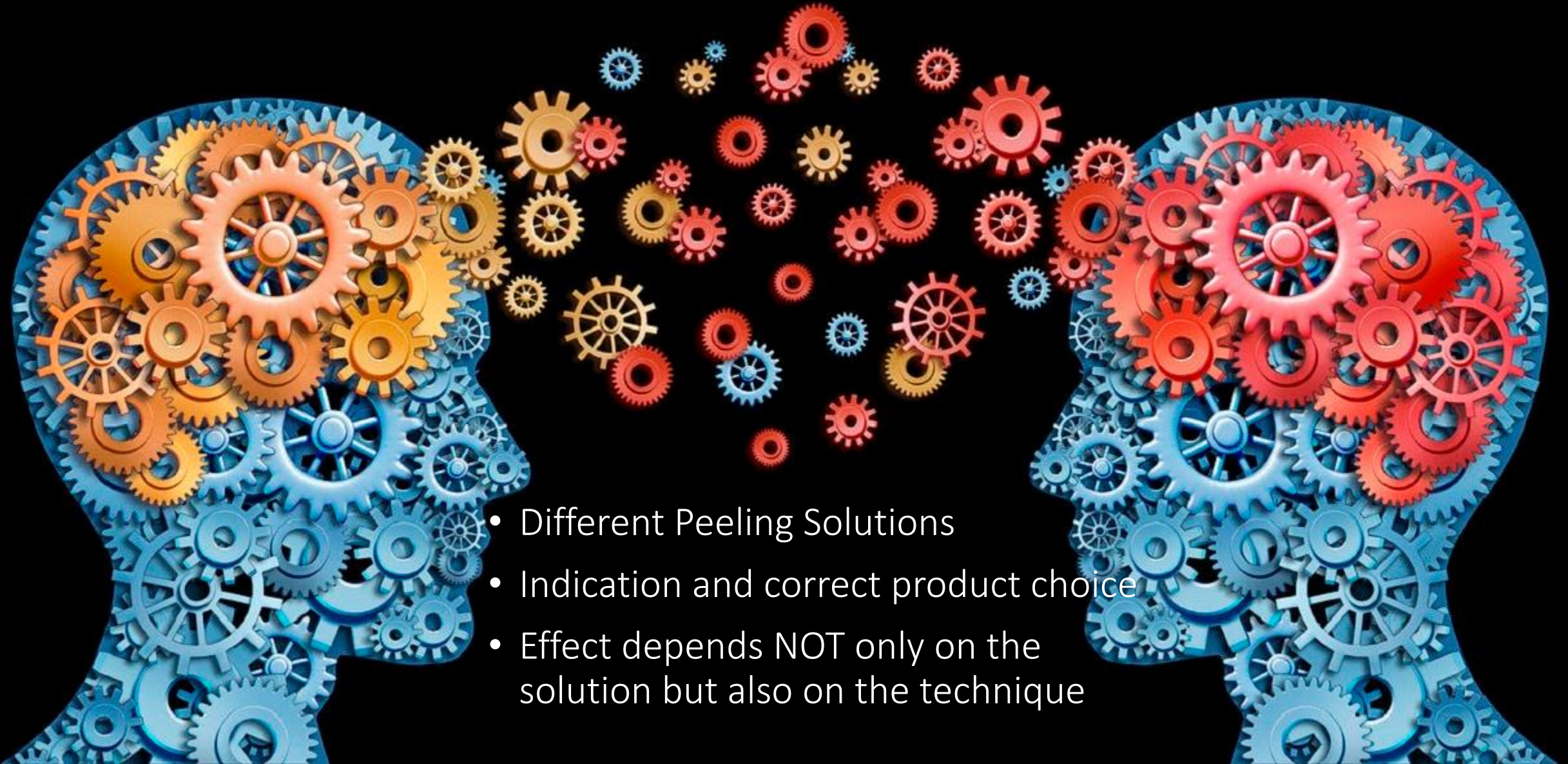
Superficial – Middle Deep – Deep



BURN



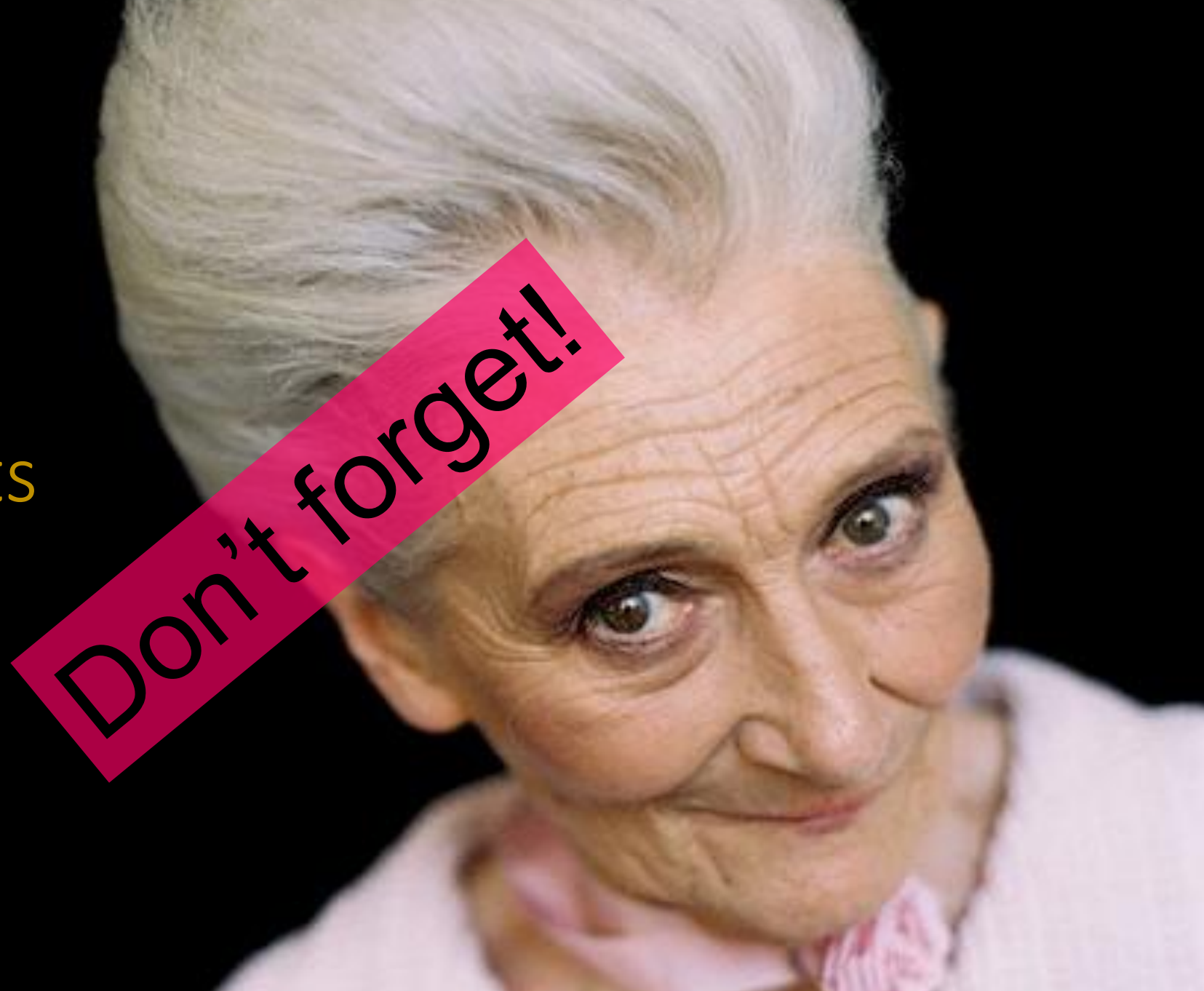Understanding



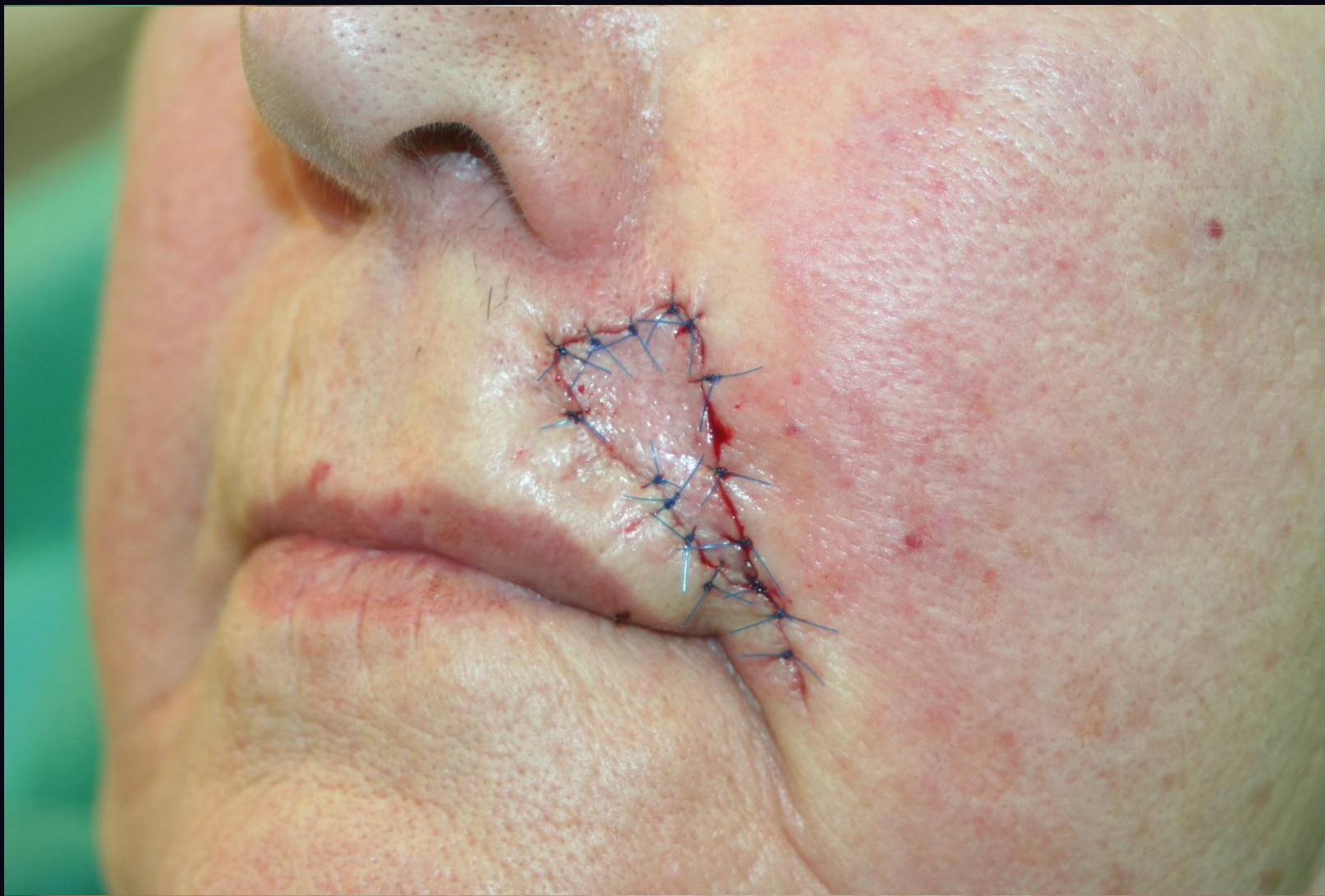- Different Peeling Solutions
- Indication and correct product choice
- Effect depends NOT only on the solution but also on the technique

aesthetic patients
can be difficult

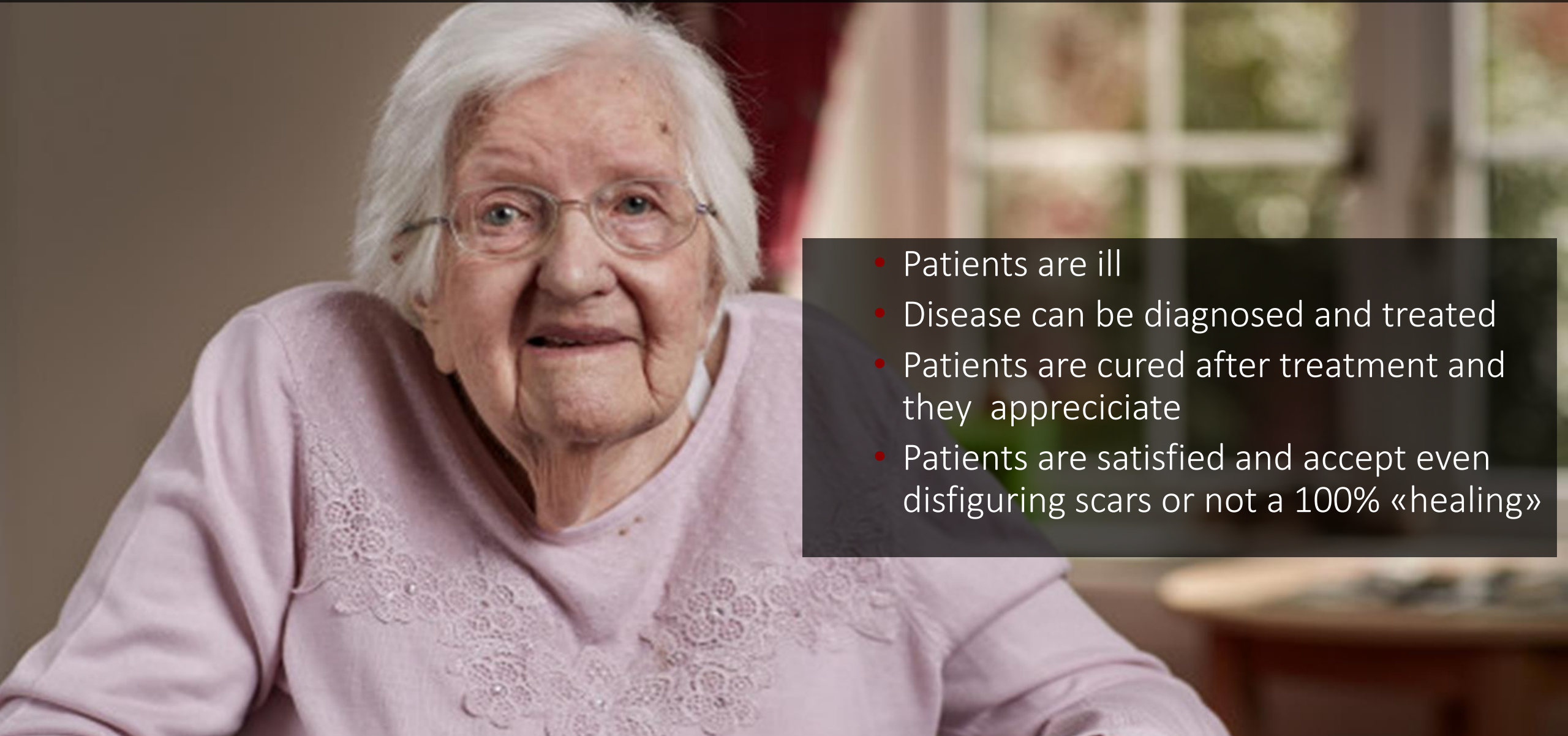Don't forget!



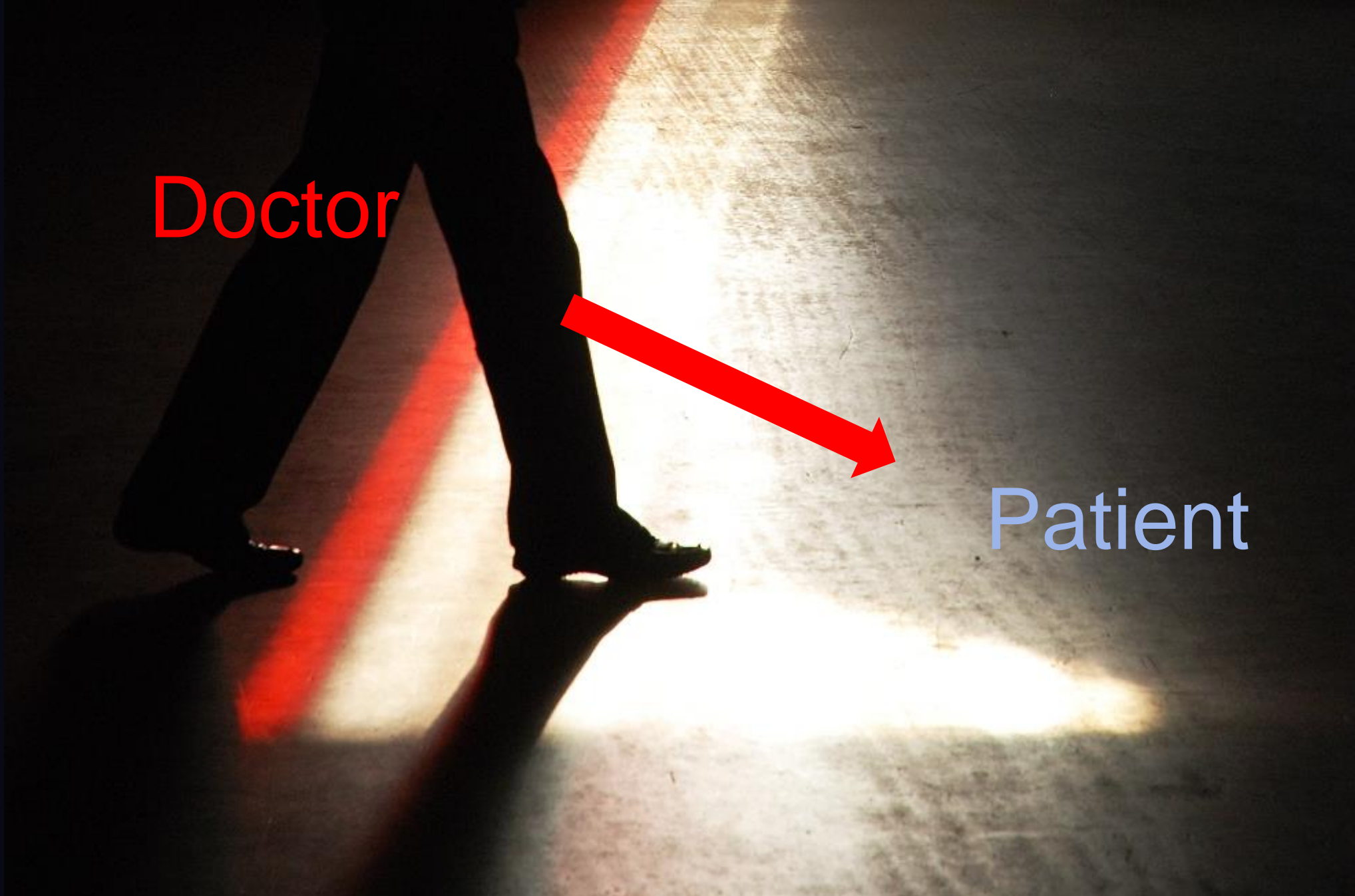



The typically Patient in Classic Dermatology?



- Patients are ill
- Disease can be diagnosed and treated
- Patients are cured after treatment and they appreciate
- Patients are satisfied and accept even disfiguring scars or not a 100% «healing»




Doctor

Patient

The aesthetic patient

- Patients are healthy
- Patients become clients
- High end clients
- Every little change will be considered as a complication
- Too less is as wrong as too much



A silhouette of a person walking is shown against a bright, circular light source on a dark floor. A red arrow points from the word 'Client' to the word 'Doctor'.

Client

Doctor



Client

Patient

Competence

- Acne vulgaris
- «Unclean» skin
- Melasma
- Beginning photoageing
- Superficial hyperpigmentation
- Very superficial wrinkles

Indication Middle Deep Peeling

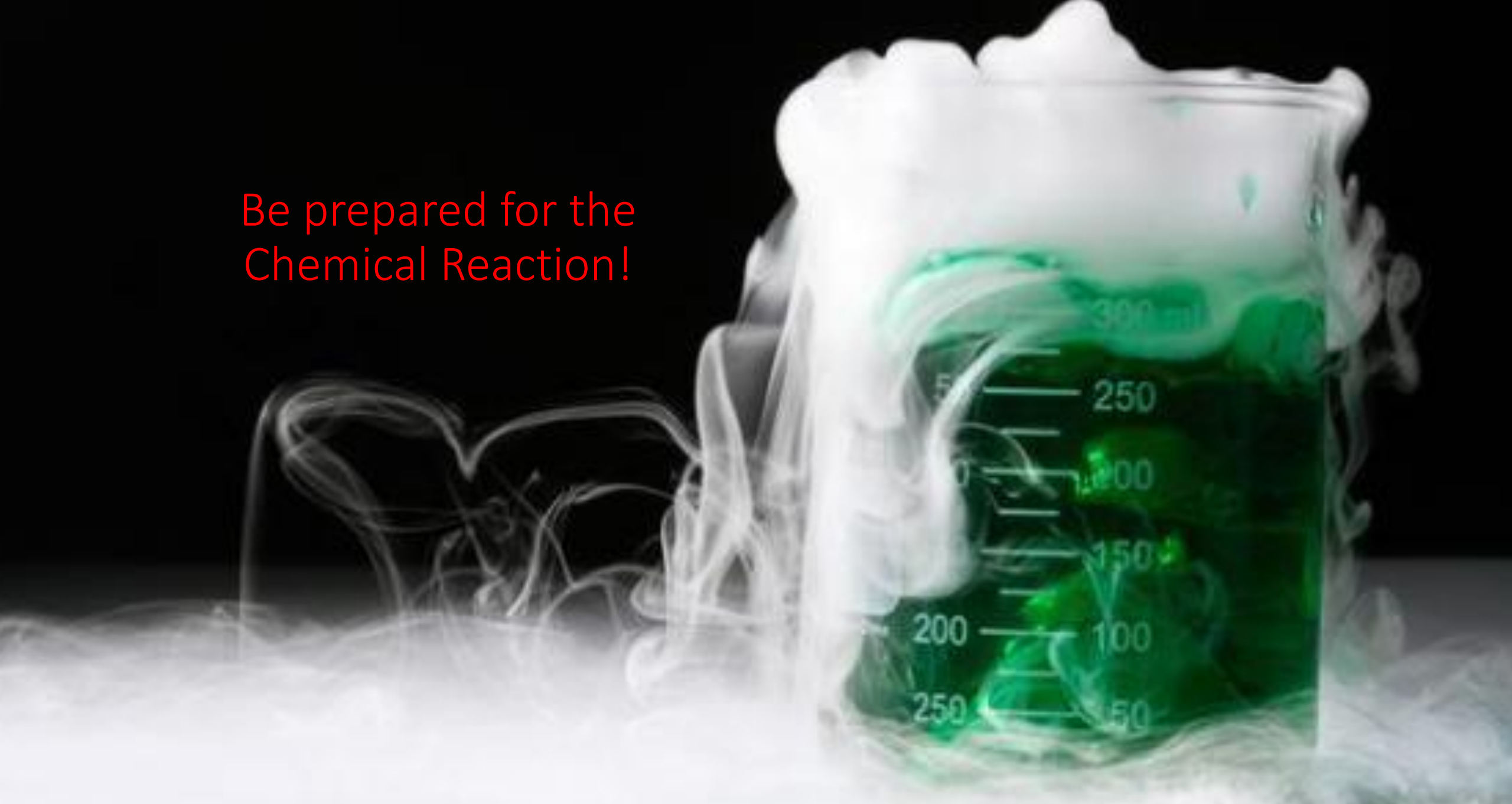Superficial wrinkles
Hyperpigmentations
Beginning Photodageing
Superficial actinic keratosis

Superficial acne scars
Lentigines
Melasma
Elastosis of the skin



Disturbance in Peeling is usual

Be prepared for the
Chemical Reaction!





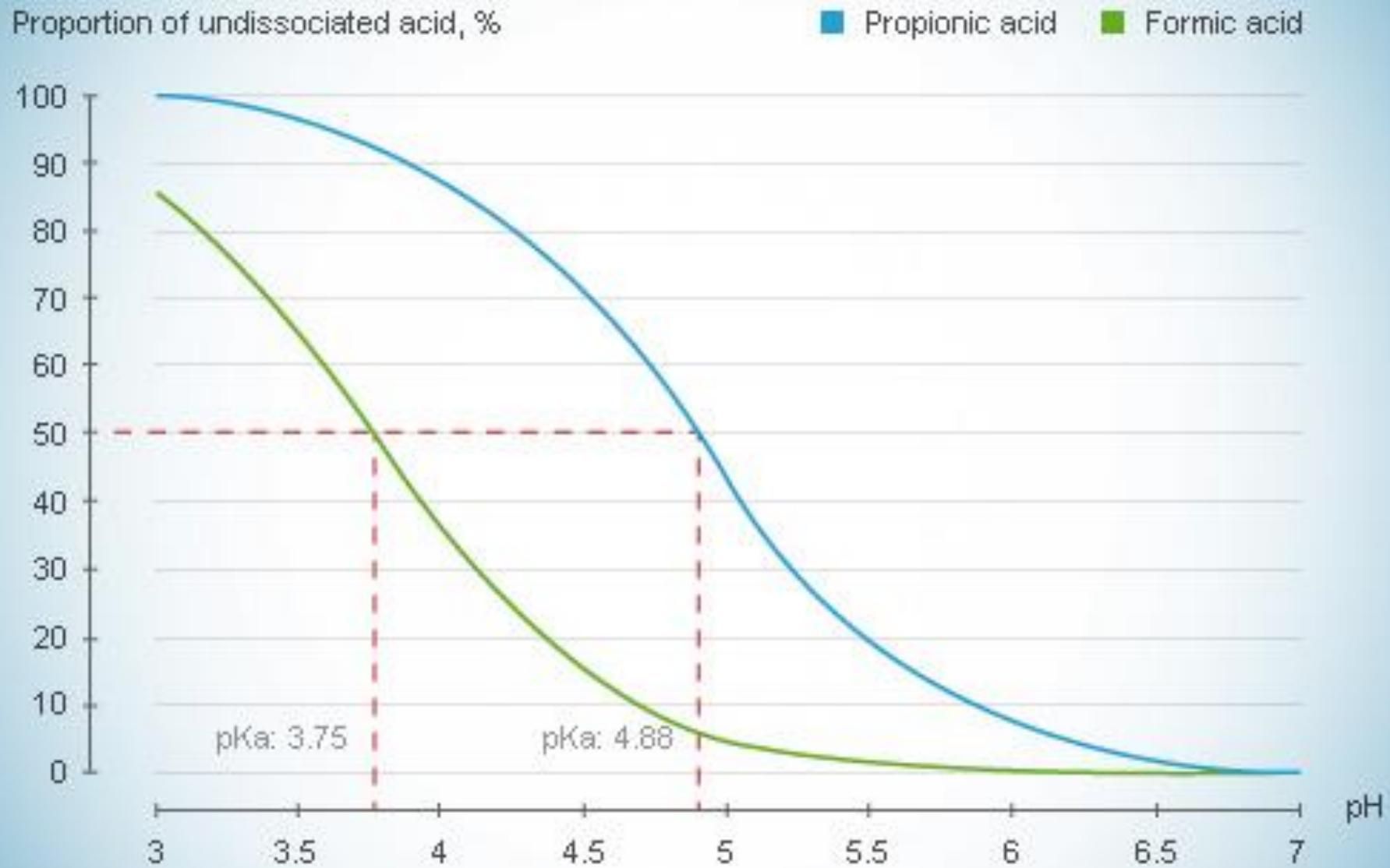
Superficial Peeling

Alphahydroxy - Acids

temporary skin improvement

Alphahydroxy Acid (AHA)

Superficial Peeling



Indication for Superficial Peeling

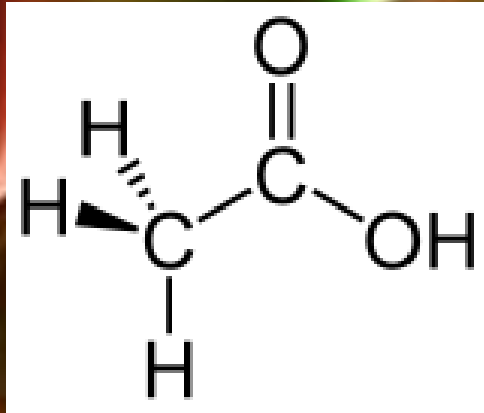
- Excellent rejuvenation after 4 sessions
- Improvement of the skin texture
- Fresh and youthful look
- Many demands in autumn before dance ball, meeting of former school class, X-Mas, New Year



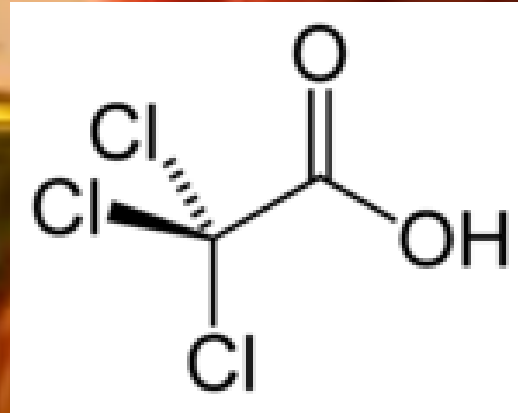
Middle Deep Peeling

TCA Peeling





Vinegar



TCA

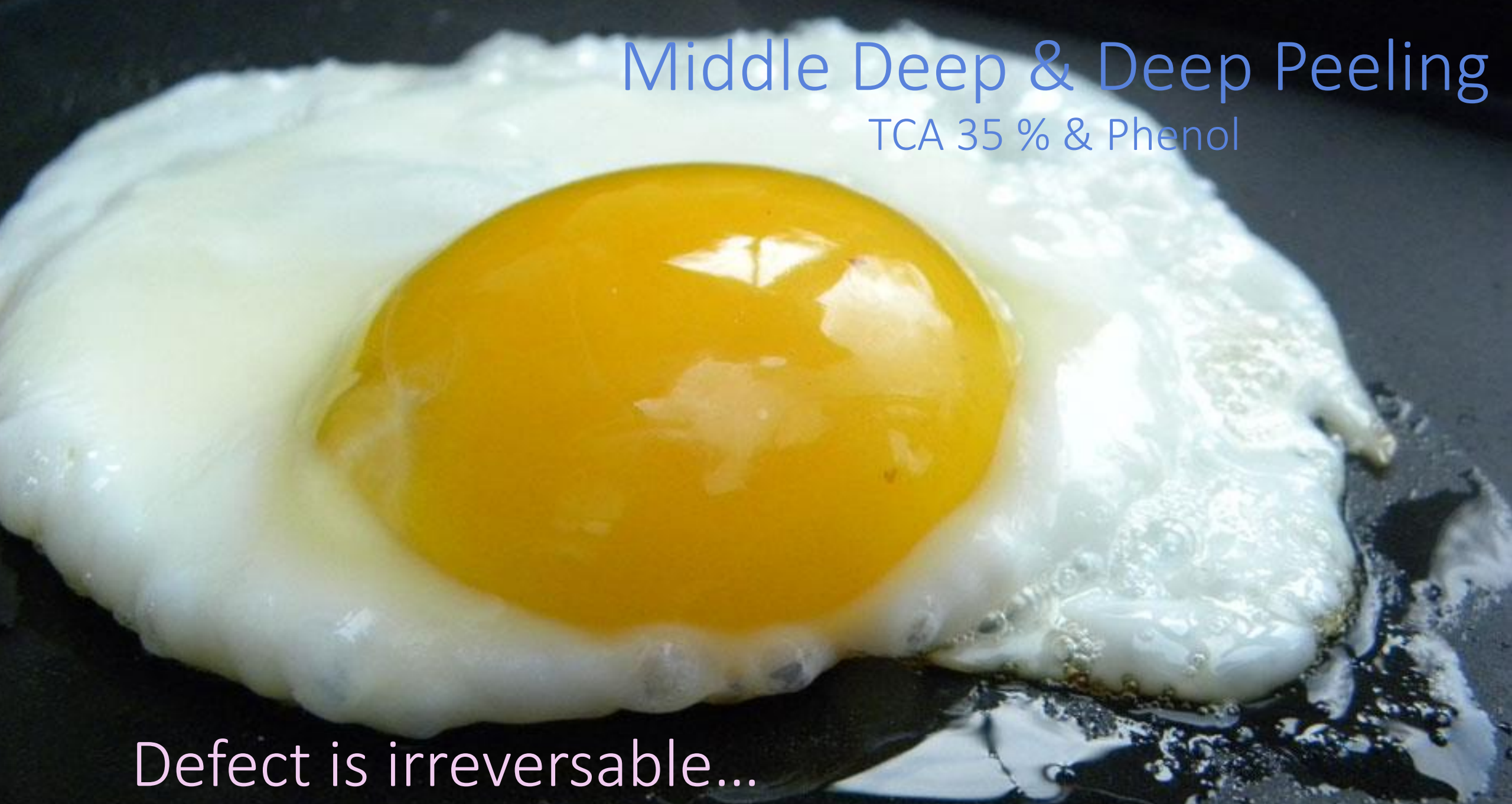Mechanism of Action - TCA

- Triple chlorinated carboxylic acid
- 15 – 35% Solutions
- Denaturation of the proteins
- Penetration depending from:
 - Concentration of the solution
 - Pretreatment
 - Condition of the skin (seborrheic, dry)
 - Application (degreasing, appl. pressure, number of passes)
 - Treatment area (seborrhic area)

Schürer NY, Wiest L. Bildatlas Peeling, 2012

Middle Deep & Deep Peeling

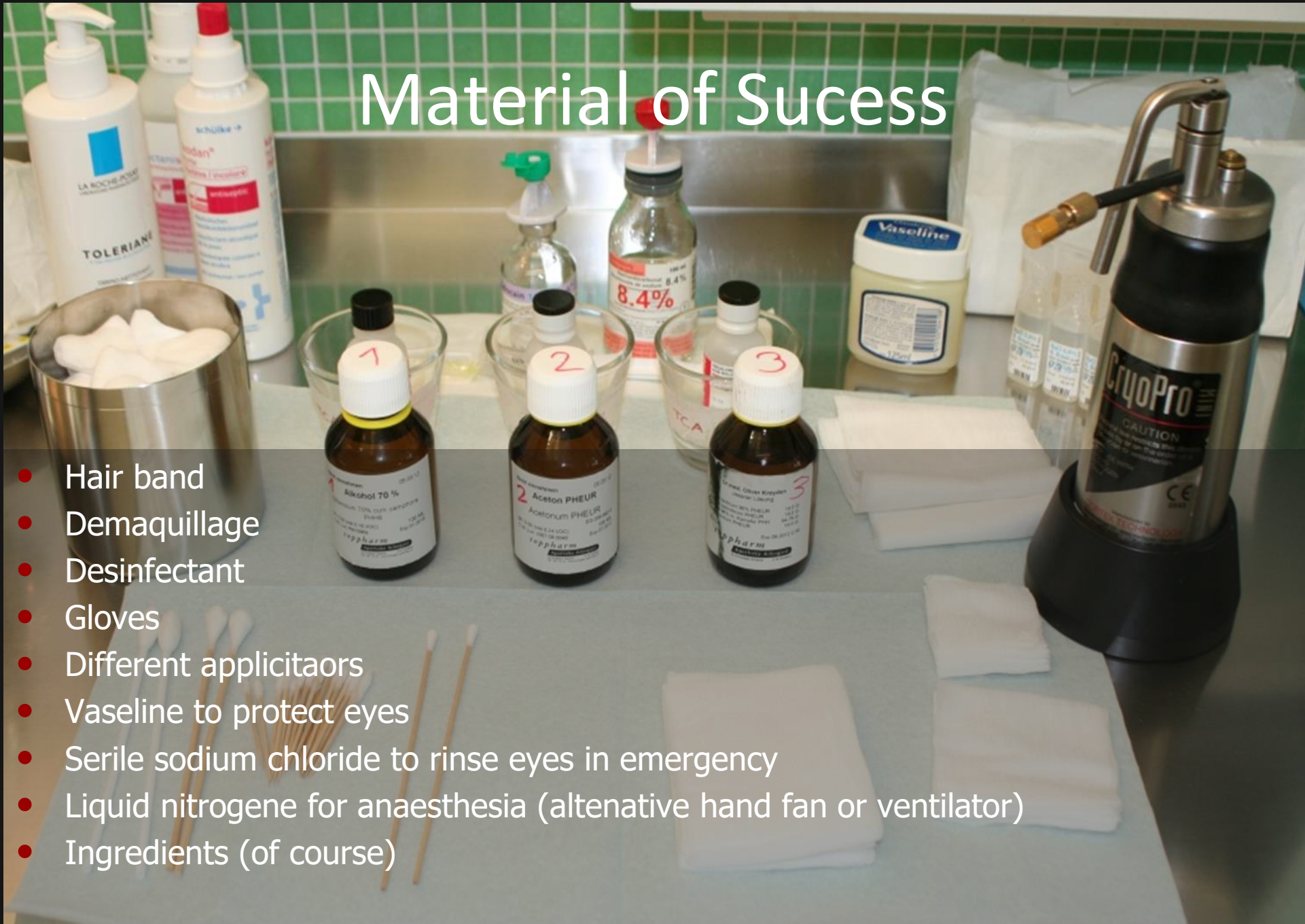
TCA 35 % & Phenol



Defect is irreversable...

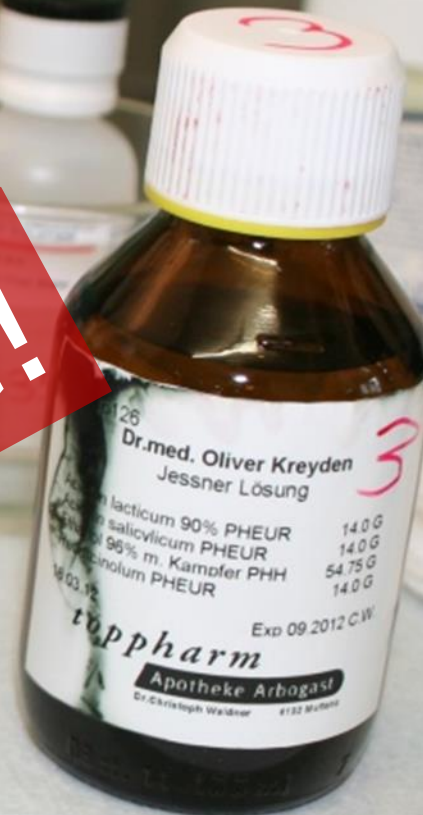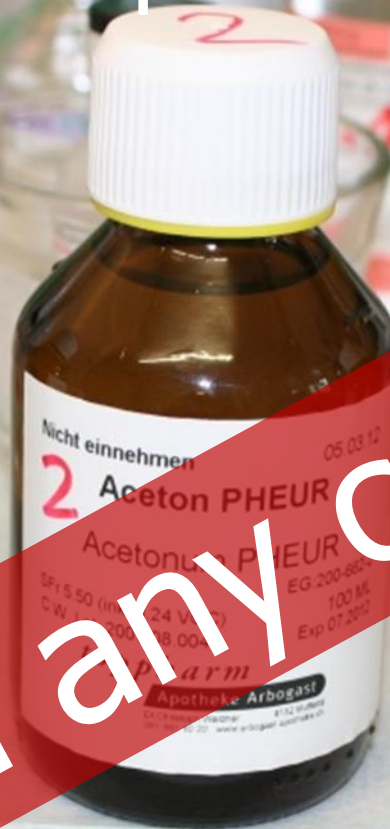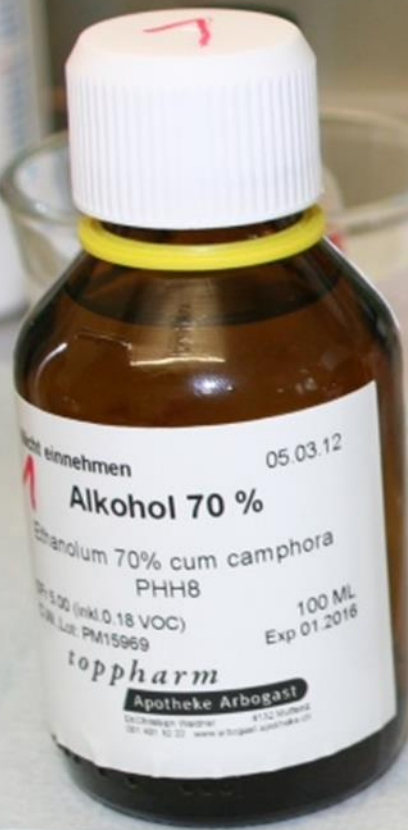Material of Success

- Hair band
- Demaquillage
- Desinfectant
- Gloves
- Different applicators
- Vaseline to protect eyes
- Sterile sodium chloride to rinse eyes in emergency
- Liquid nitrogen for anaesthesia (alternative hand fan or ventilator)
- Ingredients (of course)



4-Step Treatment

In any case!



Phenol Peeling– The Lion King in Chemical Peels




Baker Gordon Formulation

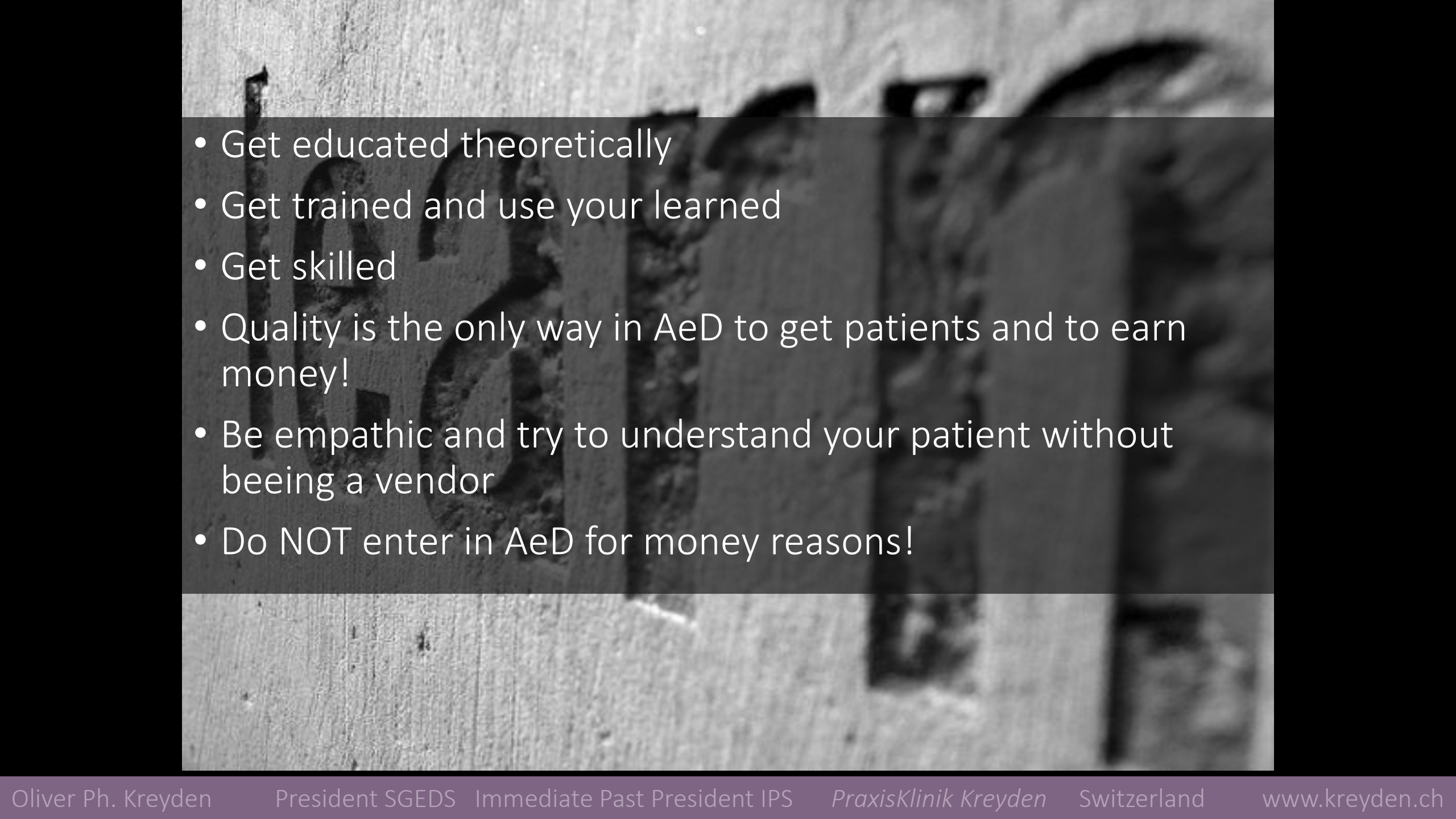
- 3.0 ml Phenol 88% USP (United States Pharmacopeia)
- 3 drops Croton Oil
- 2.0 ml d H2O
- 8 drops Hexachlorophen (0.23% in Prpylenglykol)

TCA and Phenol

- Denaturation of the proteins
- Damage is irreversible
- Regeneration of the skin via follicle system
- The more follicle the better the healing!
- Be careful in treating seborrhoeic poor areas!
- Prolonged healing
- Hyper- and hypopigmentation often

Difference between TCA and Phenol



- 
- Get educated theoretically
 - Get trained and use your learned
 - Get skilled
 - Quality is the only way in AeD to get patients and to earn money!
 - Be empathic and try to understand your patient without being a vendor
 - Do NOT enter in AeD for money reasons!

Complications

We have to distinguish mandatory side effects from unexpected complications
The deeper the peeling the more probable are side effects and complications

- Delayed wound healing
- Hyperpigmentation
- Persistent Erythema
- Teleangiectasia
- Scarring
- Herpes simplex infection
- Unsatisfied patient

To prevent Complications

- Only peel when trained!
- Systemic Herpes Simplex prophylaxis
- Get in contact with a local anaesthesiologist
- No deep peel without monitoring!
- Addapt your peeling to the clinic!
- Addapt application pressure to the frosting
- Wound controll every day after treatment
- React when it gets complicate!
- If everything smooth be smooth as well!

How to do it then?





Get trained!

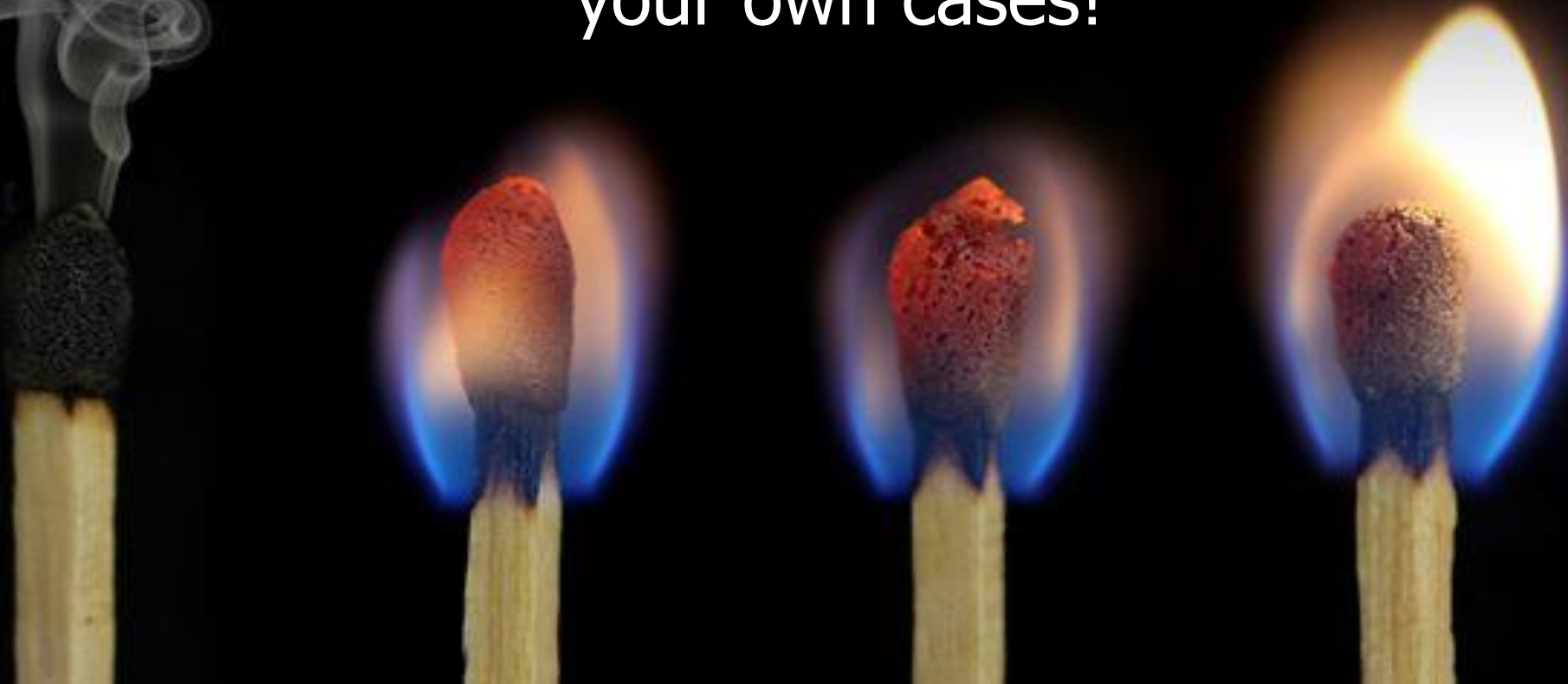


Do your first peel!

- Beginn with patient you know, where you have already a band of trust
- Start with superficial peelings
- Do it «lege artis» without any compromise

Control, Control, Control!

Be critical to yourself and learn of
your own cases!



Dont be a photocopier...



Be a Doctor!



Dr. Neighbour





Hyperhidrosis Live-Course

Facial Live-Course

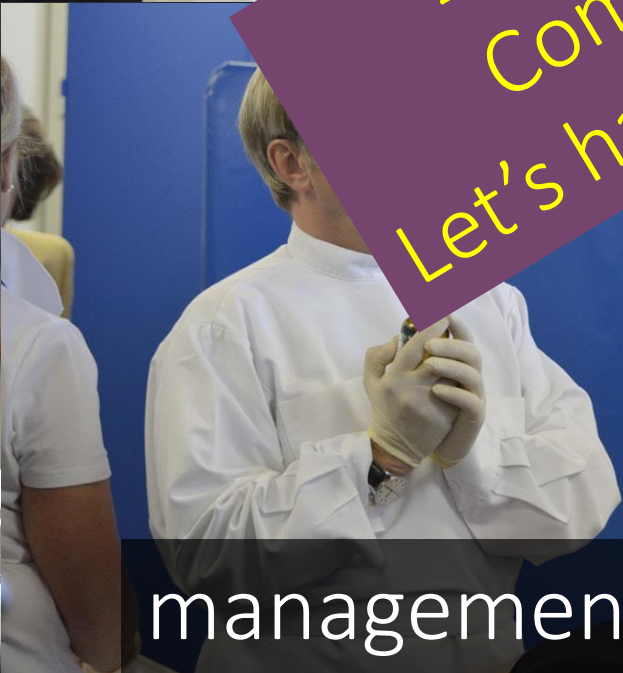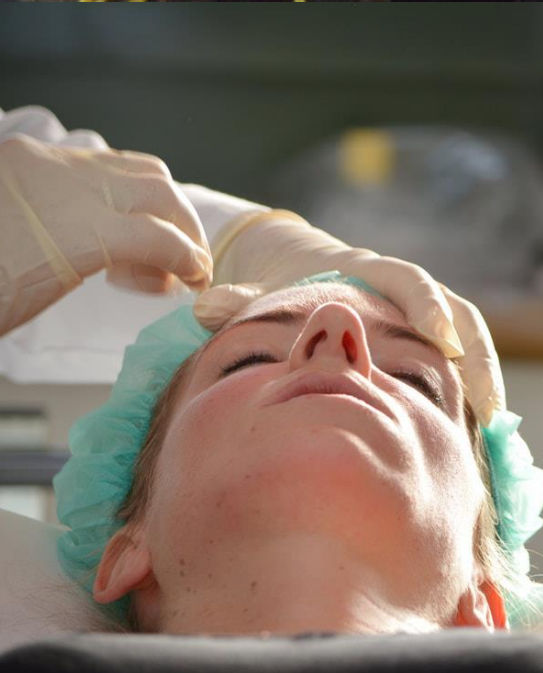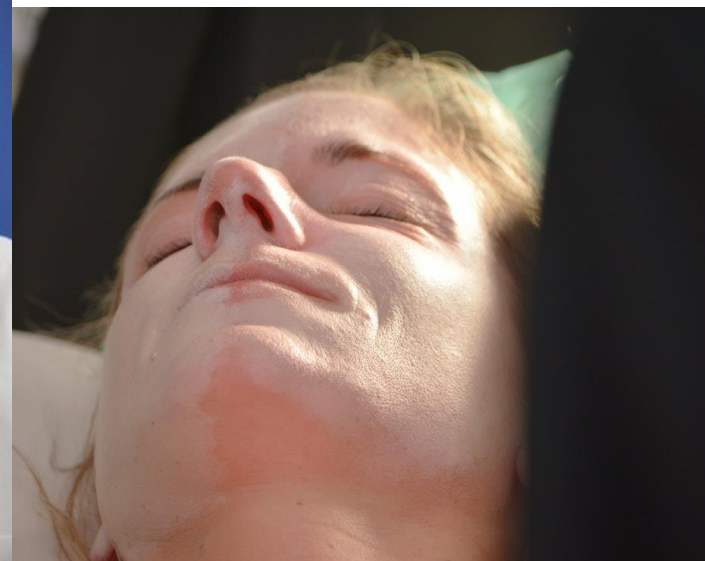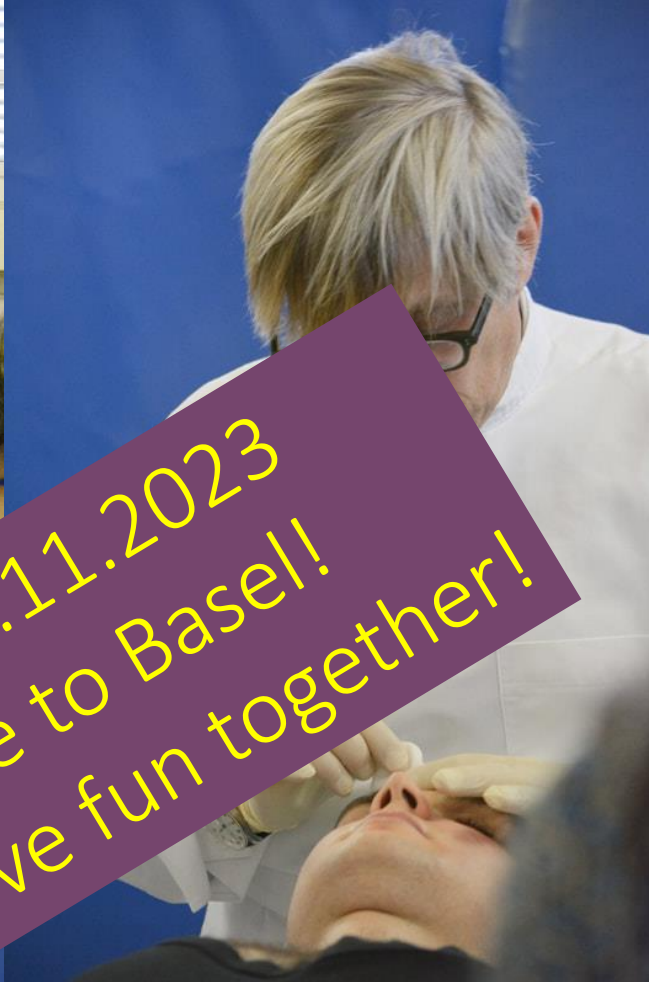Peeling Live-Course

management@kreyden.ch



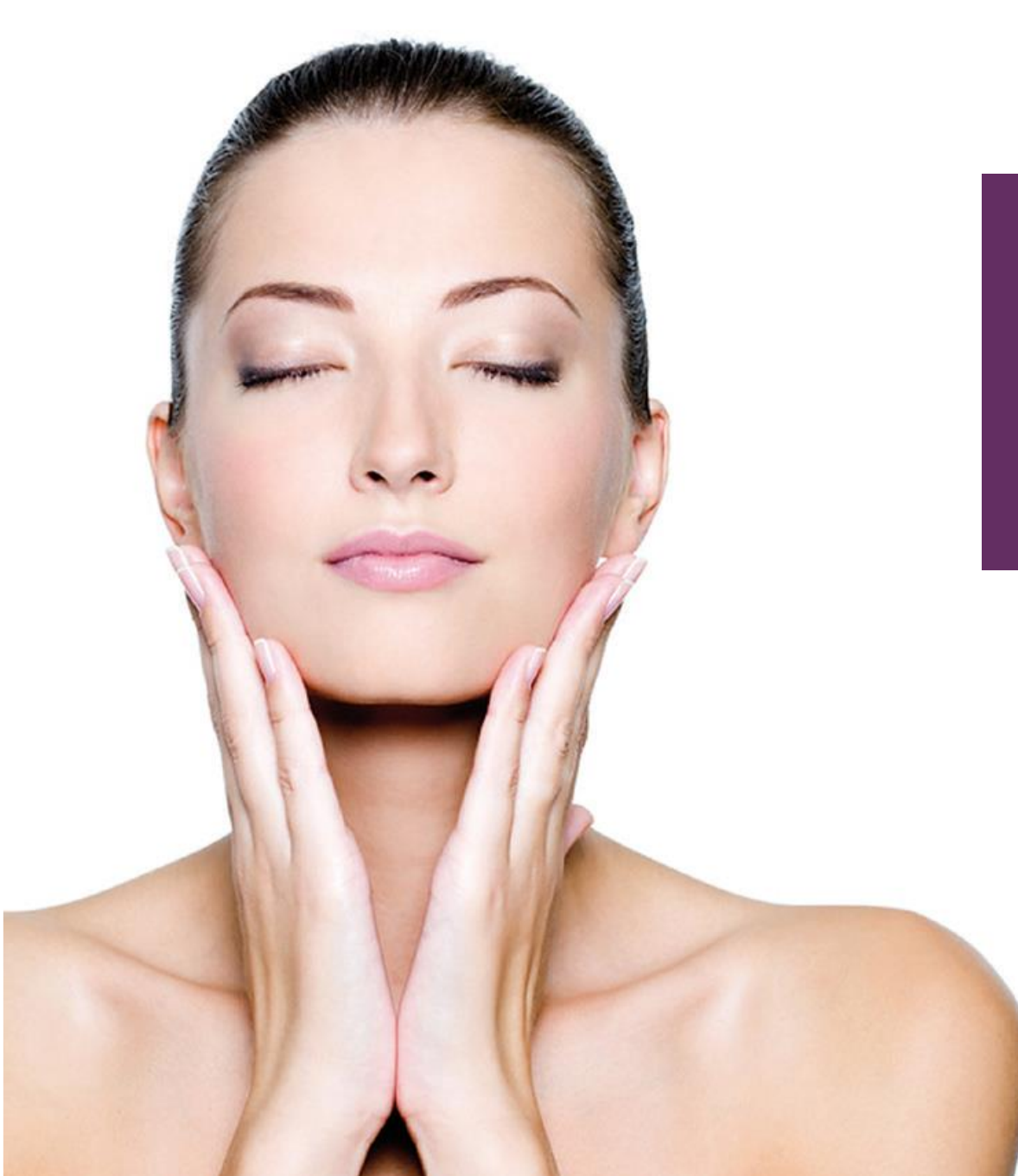SWISS GROUP FOR ESTHETIC
DERMATOLOGY & SKINCARE





17.- 18.11.2023
Come to Basel!
Let's have fun together!

management@kreyden.ch



BECOME A MEMBER

www.peelingsociety.com



SWISS GROUP FOR ESTHETIC
DERMATOLOGY & SKINCARE